

**Compendium in ear-reflexology,
version 20120204.**

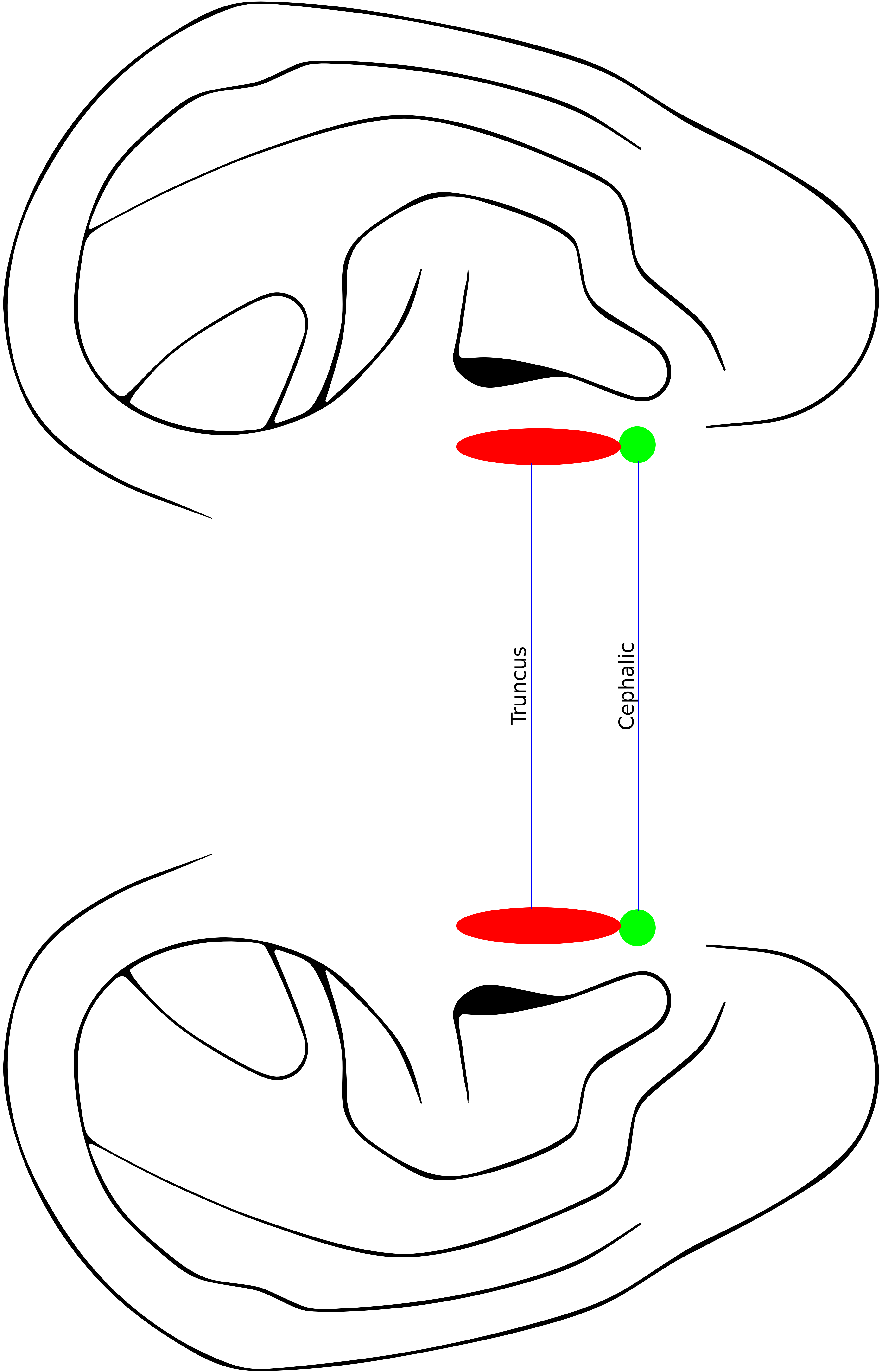
Arve Fahlvik

**Much of the content of this document is based on text
and ideas as it appears in the work of reflexologist
Karl Axel Lind.**

Sourcefiles for graphics can be provided on request.

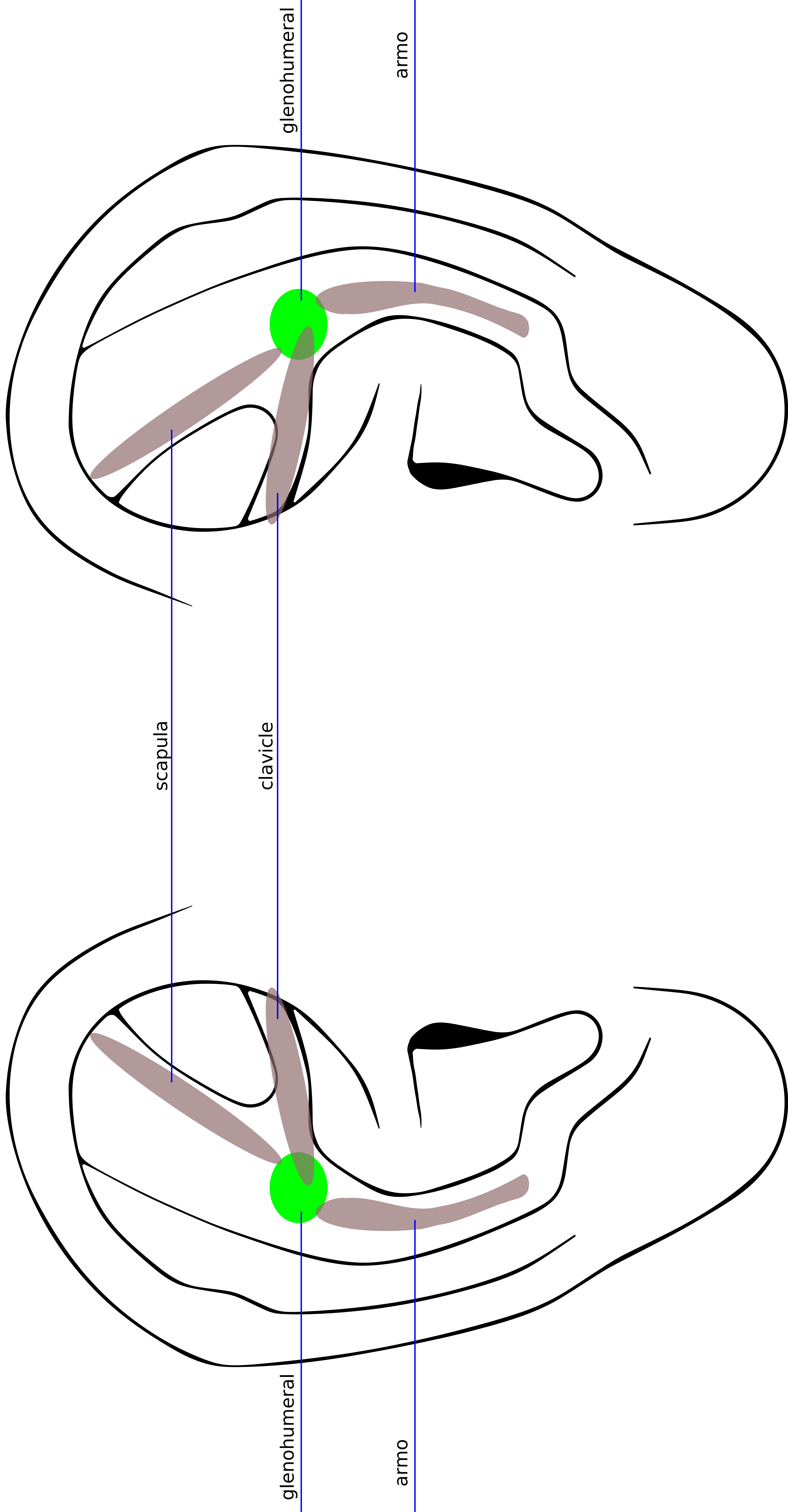


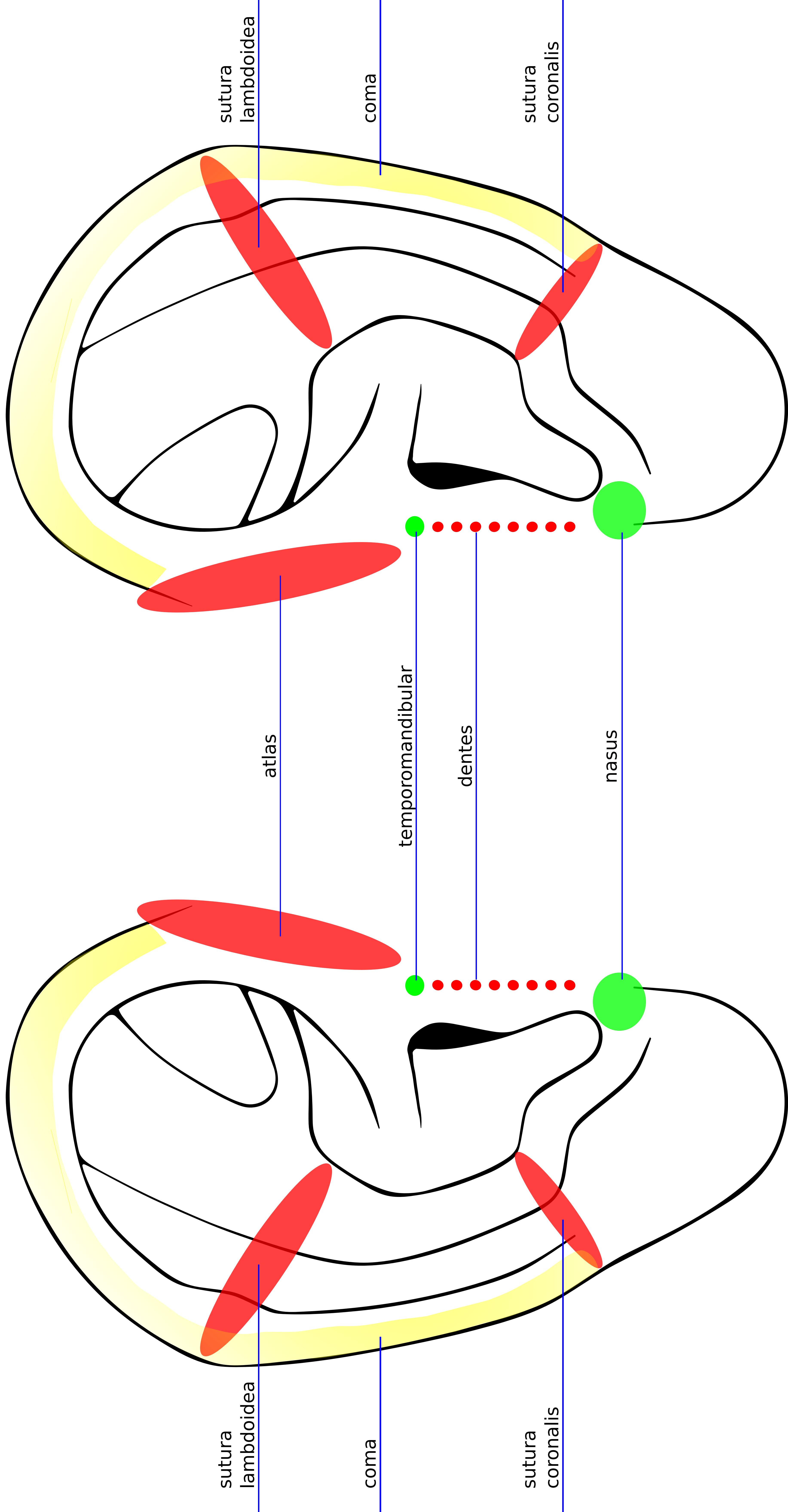
**This document is licensed under the
Attribution-NonCommercial-ShareAlike 3.0 Unported
license, available at
<http://creativecommons.org/licenses/by-nc-sa/3.0/>.**

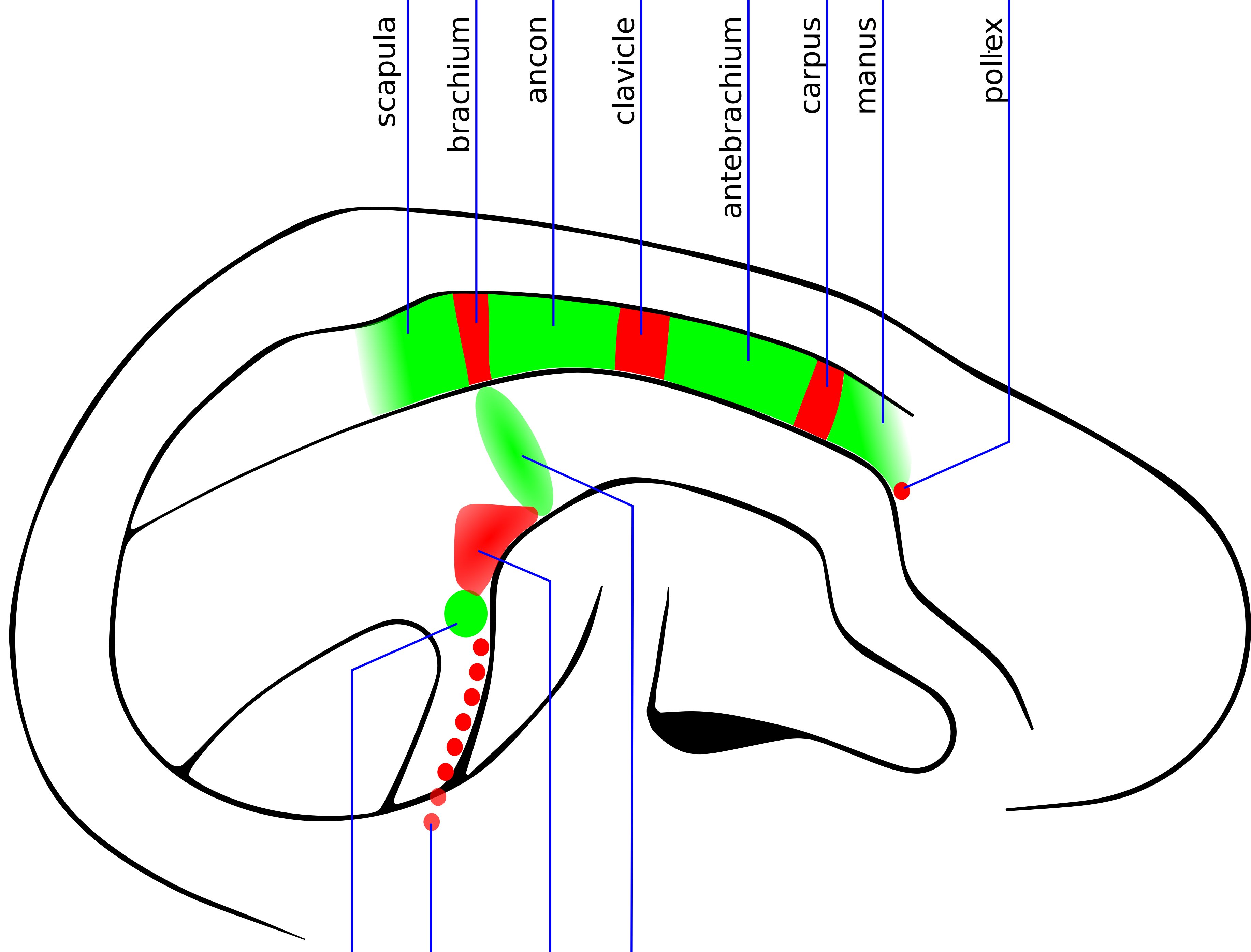


Truncus

Cephalic





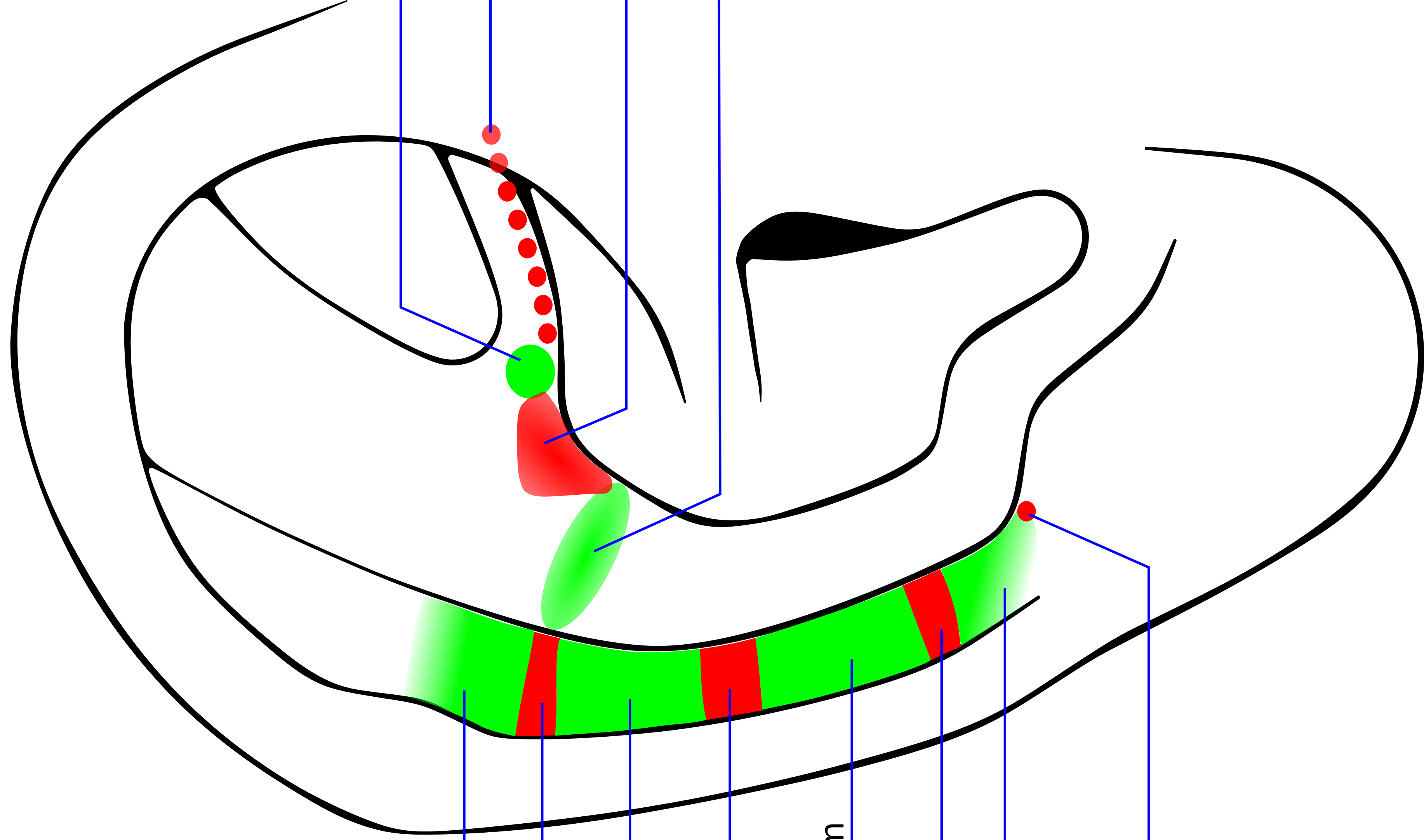


temporomandibular

dentes

cervix

clavicle



scapula

brachium

ancon

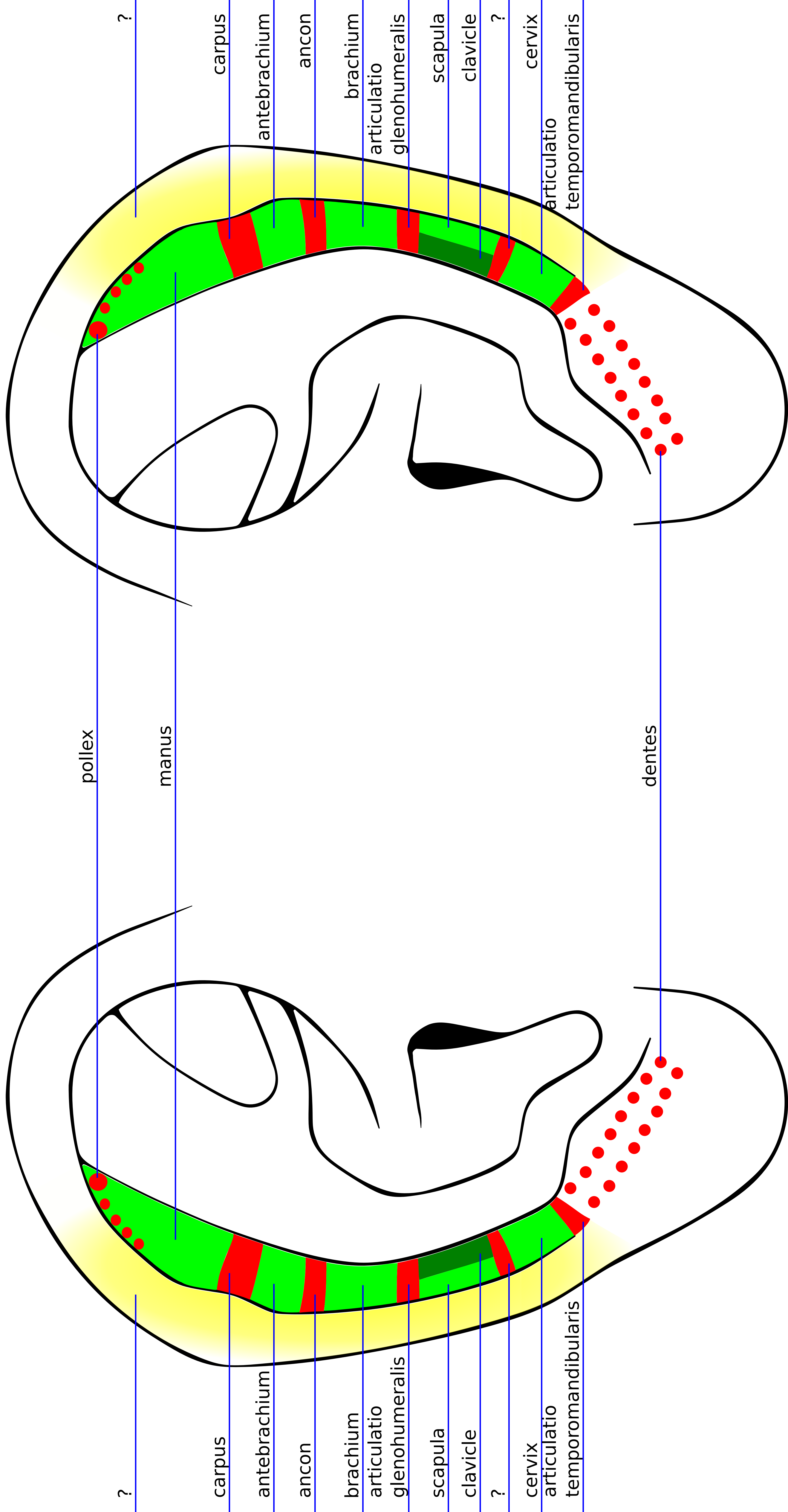
clavicle

antebrachium

carpus

manus

pollex



pollex

manus

?

carpus

antebrachium

ancon

brachium

articulatio

glenohumeralis

scapula

clavicle

?

cervix

articulatio

temporomandibularis

?

carpus

antebrachium

ancon

brachium

articulatio

glenohumeralis

scapula

clavicle

?

cervix

articulatio

temporomandibularis

dentes

